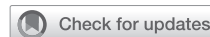

Adverse reactions to drugs and biologics in patients with clonal mast cell disorders: A Work Group Report of the Mast Cells Disorder Committee, American Academy of Allergy, Asthma & Immunology



Melody C. Carter, MD,^a Dean D. Metcalfe, MD,^a Almudena Matito, MD, PhD,^{b,d} Luis Escribano, MD, PhD,^{c,d} Joseph H. Butterfield, MD,^e Lawrence B. Schwartz, MD, PhD,^f Patrizia Bonadonna, MD,^{g,h} Roberta Zanotti, MD,^{h,i} Massimo Triggiani, MD,^j Mariana Castells, MD, PhD,^k and Knut Brockow, MD^l *Bethesda, Md, Toledo and Salamanca, Spain, Rochester, Minn, Richmond, Va, Verona and Salerno, Italy, Boston, Mass, and Munich, Germany*

AAAAI Position Statements, Work Group Reports, and Systematic Reviews are not to be considered to reflect current AAAAI standards or policy after five years from the date of publication. The statement below is not to be construed as dictating an exclusive course of action nor is it intended to replace the medical judgment of healthcare professionals. The unique circumstances of individual patients and environments are to be taken into account in any diagnosis and treatment plan. The statement reflects clinical and scientific advances as of the date of publication and is subject to change.

For reference only.

Providers caring for patients with mastocytosis are tasked with the decision to consider therapeutic options. This can come with some trepidation because information available in the public domain lists numerous mast cell (MC) activators based on data that do not discriminate between primates, rodents, and MC lines; do not consider dosage; and do not take into account previous exposure and resultant clinical findings. This being said, there is support

in the literature for an enhanced MC response in some patients with mastocytosis and in cases in which there is a greater incidence of adverse reactions associated with certain antigens, such as venoms and drugs. Thus this report provides a comprehensive guide for those providers who must decide on therapeutic options in the management of patients with clonal MC disease. (*J Allergy Clin Immunol* 2019;143:880-93.)

From ^athe Laboratory of Allergic Diseases, National Institute of Allergy and Infectious Diseases, National Institutes of Health, Bethesda; ^bInstituto de Estudios de Mastocitosis de Castilla-La Mancha (CLMast), Hospital Virgen del Valle, Toledo; ^cServicio General de Citometría, Centro de Investigación del Cáncer/IBMCC (USAL/CSIC) and Departamento de Medicina, Universidad de Salamanca and IBSAL, Salamanca; ^dthe Spanish Network on Mastocytosis (REMA), Toledo; ^ethe Division of Allergic Diseases and the Program for Mast Cell and Eosinophil Disorders, Mayo Clinic, Rochester; ^fthe Department of Internal Medicine, Virginia Commonwealth University, Richmond; ^gthe Allergy Unit and ^hthe Multidisciplinary Outpatients Clinic for Mastocytosis (GISM), and ⁱthe Department of Medicine, Haematology Unit, Azienda Ospedaliera Universitaria Integrata of Verona; ^jthe Division of Allergy and Clinical Immunology, University of Salerno; ^kBrigham and Women's Hospital, Harvard Medical School, Boston; and ^lthe Department of Dermatology and Allergy Biederstein, Technical University of Munich, Munich.

Supported by the Division of Intramural Research of the National Institute of Allergy and Infectious Diseases/National Institutes of Health.


Disclosure of potential conflict of interest: J. H. Butterfield receives royalties from Millipore. L. B. Schwartz received consultancy fees from Deciphera and Genentech.

R. Zanotti received consultancy fees from Deciphera. M. Castells receives royalties from UpToDate and Elsevier Publishing; received consultancy fees from Sanofi, Merck, ContraFect, Arete Discoveries, and Betham Science; and received an honorarium from the American College of Allergy, Asthma, and Immunology Colombian Allergy Association. The rest of the authors declare that they have no relevant conflicts of interest.

Received for publication April 10, 2018; revised September 6, 2018; accepted for publication October 9, 2018.

Available online December 6, 2018.

Corresponding author: Melody C. Carter, MD, Building 10/11C207, 10 Center Dr, MSC 1881, Bethesda, MD 20892-1881. E-mail: mcarter@niaid.nih.gov.

 The CrossMark symbol notifies online readers when updates have been made to the article such as errata or minor corrections

0091-6749/\$36.00

© 2019 Published by Elsevier Inc. on behalf of the American Academy of Allergy, Asthma & Immunology

<https://doi.org/10.1016/j.jaci.2018.10.063>

Key words: Mastocytosis, tryptase, Hymenoptera, anesthesia, nonsteroidal anti-inflammatory drugs, monoclonal antibodies, radiocontrast media, vaccines

Mastocytosis is a proliferative disorder of hematopoietic mast cell (MC) progenitors, leading to expansion and accumulation of excessive numbers of MCs in 1 or more organs, such as the skin, bone marrow, gastrointestinal tract, liver, and spleen.¹ There are reports in the literature that patients with mastocytosis have a higher incidence of adverse reactions associated with exposure to pharmacologic agents and venoms. In this work we review these reports to facilitate appropriate therapeutic decisions by caregivers caring for patients with mastocytosis.

The prevalence of overt mastocytosis has been estimated to be about 10 cases per 100,000 persons.² The molecular basis of the disease in most cases is an activating mutation in *KIT*, a protein tyrosine kinase receptor for stem cell factor.³ More than 80% of all patients with systemic mastocytosis (SM) carry a point mutation with exchange of aspartic acid to valine in codon 816 (D816V). Whereas in children the majority of patients have accumulations of MCs only in the skin (cutaneous mastocytosis [CM]), in adults internal organs are usually affected and thus they are given the diagnosis of SM.¹

According to the World Health Organization, to diagnose SM, several criteria have to be fulfilled, including MC aggregates in the bone marrow or extracutaneous tissue, spindle-shaped MCs in bone marrow smears, aberrant CD25 expression by MCs, detection of an activating mutation in *c-Kit*, and serum tryptase levels of greater than 20 ng/mL (Table I).⁴ The prevalence of systemic involvement in adults with mastocytosis exceeds 90% with optimal detection methods. SM is subdivided into different clinical variants according to pathology, aggressiveness, and prognosis. The most common form (approximately 90% of all patients) is indolent systemic mastocytosis (ISM). Rare advanced forms are SM with an associated hematologic disorder, aggressive SM, and MC leukemia.⁴

Anaphylaxis is a generalized life-threatening systemic hypersensitivity reaction.⁵ Clinical criteria for the diagnosis of anaphylaxis have been defined.⁶ The incidence and severity of anaphylaxis is 4 to 6 times greater in patients with mastocytosis compared with that in the general population.⁷⁻⁹ In children with mastocytosis, a significantly increased risk of anaphylaxis appears to be associated with extensive skin involvement and high serum tryptase levels,^{7,10} especially during blistering episodes.¹¹ In adults with mastocytosis, the cumulative prevalence of anaphylaxis has been reported to be between 22% and 49% of patients.^{7,9,12} Those with ISM have an increased risk of anaphylaxis compared with those with cutaneous disease.⁷ Anaphylaxis in patients with mastocytosis with skin involvement was associated with greater basal serum tryptase levels compared with those in subjects without mastocytosis in the skin (MIS).¹³ In patients with ISM without MIS, the diagnosis is mostly recognized after patients had anaphylaxis and were found to have an increased basal serum tryptase level, which led to the suspicion of mastocytosis. In patients with ISM without MIS, there is a male predominance and history of insect sting-induced anaphylaxis.¹³

In addition to patients with SM, there are patients with anaphylaxis who carry clonal MCs expressing the D816V *c-Kit* mutation but do not meet enough criteria for the diagnosis of mastocytosis. This condition, when associated with an episode-related increase in serum tryptase levels, is referred to as monoclonal MC activation syndrome and can be associated

Abbreviations used

CM:	Cutaneous mastocytosis
CMD:	Clonal mast cell disease
DCM:	Diffuse cutaneous mastocytosis
HVA:	Hymenoptera venom allergy
ISM:	Indolent systemic mastocytosis
MC:	Mast cell
MIS:	Mastocytosis in the skin
MMR:	Measles, mumps, rubella
NSAID:	Nonsteroidal anti-inflammatory drug
PG:	Prostaglandin
RCM:	Radiocontrast media
SM:	Systemic mastocytosis
TX:	Thromboxane
VIT:	Venom immunotherapy

with Hymenoptera venom-induced anaphylaxis or anaphylaxis of unknown origin.^{9,14-16}

Hymenoptera venoms are the most frequently reported elicitors of anaphylaxis in patients with mastocytosis.^{7,9,12} The severity of these reactions in patients with mastocytosis appears to be increased compared with that in subjects without mastocytosis.^{7,17} Although it is not uncommon that patients with idiopathic anaphylaxis have received diagnoses of mastocytosis, the association between mastocytosis and drug- or food-induced anaphylaxis does not appear to be as strong as the association with insect venom-induced anaphylaxis.¹⁶ One study of 137 patients with drug- or food-induced anaphylaxis reported only 2 patients with a diagnosis of mastocytosis.¹⁷ Yet many cases of anaphylaxis in patients with mastocytosis documented in case series or individual case reports appear to be related to general anesthesia, opioids, contrast medium, and a variety of other agents.

The aim of this article is to present a review of available data on the risk of drug-induced anaphylaxis in patients with mastocytosis and to form a consensus among experts on how to manage patients with mastocytosis in need of such therapy.

ADVERSE DRUG REACTIONS DURING ANESTHESIA

Anesthetic procedures can induce MC mediator release associated with mechanical irritation of tissues, stress, or drugs, such as neuromuscular blockers, opioids, hypnotics, and analgesics.¹⁸⁻²³ Based on such observations, anesthetic procedures are considered to generate greater risk in patients with mastocytosis justified by reports of severe reactions (eg, systemic hypotension, anaphylaxis, and coagulopathy) resulting in patient death.²⁴⁻³³

The incidence of perioperative anaphylaxis was reported to be 0.4% in one adult series of patients with mastocytosis³⁴ and ranged from 0% to 2% in a pediatric series.^{18,34-37} In the adult series³⁴ the frequency was significantly higher in cases that presented with anaphylaxis, underwent major surgeries and general anesthesia, and were not given prophylactic antimediator therapy 1 hour before anesthesia. Within these series, the authors found a high frequency of uneventful anesthetic procedures without any fatalities among these patients, although all authors recommended a careful management approach, avoiding known triggers that precipitated prior episodes and potential triggers, such as

TABLE I. World Health Organization criteria for the diagnosis of SM

	Criteria for SM*
Major criterion	<ul style="list-style-type: none"> ● Multifocal dense aggregates of ≥ 15 MCs in bone marrow and/or in sections of other extracutaneous organs
Minor criteria	<ul style="list-style-type: none"> ● Greater than 25% of all MCs are atypical cells on bone marrow smears or are spindle shaped in MC infiltrates detected on sections of visceral organs. ● Aberrant expression of CD25 and/or CD2 by MCs in bone marrow or other extracutaneous organs ● Codon 816 <i>c-Kit</i> point mutation in bone marrow or other extracutaneous organs ● Baseline serum tryptase levels >20 $\mu\text{g/L}$ (in case of an unrelated myeloid neoplasm, this item is not valid)

*One major and 1 minor or 3 minor criteria are required for diagnosing SM.

pharmacological, psychological, and mechanical factors and temperature changes. The reported incidence in patients with mastocytosis is thus greater than that in the general population, which is 0.01%.³⁸

There is no true consensus regarding the administration of prophylactic antimediator therapy in patients with mastocytosis.^{18,34-37} Furthermore, the utility of prophylactic antimediator therapy has not been evaluated in placebo-controlled trials. Some authors recommend maintaining the regularly scheduled treatment of antimediator therapy (eg, histamine antagonists and antileukotrienes) before surgery^{18,19,35,37} and maintaining their scheduled medications postoperatively. Others strongly recommend administration of prophylactic antimediator therapy before every anesthetic procedure in part based on the results of a retrospective study reporting the management of 459 adults and 42 children with mastocytosis who underwent a total of 676 and 50 anesthetic procedures, respectively (Table II).^{4,34} In this series one pediatric patient who presented with perioperative anaphylaxis during general anesthesia tolerated the same anesthetic drugs later when prophylactic antimediator therapy was given.³⁴ In addition, some authors focus on the possibility of anxiety facilitating MC degranulation and thus recommend perioperative sedative drugs.^{19,34} Thus there is insufficient scientific evidence on whether to recommend obligatory premedication of prophylactic antimediator therapy in every patient with mastocytosis. However, premedication is recommended by the authors in patients with previous perioperative anaphylaxis if the culprit agent has not been identified.

A cautious approach is to choose those drugs with low capacity to elicit MC degranulation *in vivo* or *in vitro* and to use drugs with known tolerance by individual patients, although the benefit of such a strategy has not been scientifically investigated. This applies to each pharmacologic group (eg, aminosteroids, neuromuscular blockers, short-acting synthetic opioids, and amide derivatives among local anesthetics). *In vitro* studies have reported that atracurium, for example, releases histamine from MCs isolated from human skin, lung, and heart tissue at much lower concentrations and much greater maximal levels than vecuronium or d-tubocurarine, whereas succinylcholine did not release histamine from MCs.³⁹ In another study succinylcholine and cisatracurium had the lowest potency for

MC activation. The aminosteroids (vecuronium, rocuronium, pancuronium, and rapacuronium) demonstrated intermediate potency in inducing MC degranulation, whereas atracurium and mivacurium were the most potent activators identified by *in vivo* studies of MCs using dermal microdialysis combined with laser Doppler imaging.⁴⁰ An additional study compared equipotent doses of vecuronium and cisatracurium for chemical, systemic, and cutaneous release of histamine. Six minutes after induction with thiopental, there was no increase in histamine levels or cardiovascular effects associated with use of these neuromuscular blockers.⁴¹

With regard to clinical outcomes in the general population, some studies have reported that the neuromuscular blockers more frequently involved in anaphylaxis during anesthesia are succinylcholine (60.6%) and atracurium (19.6%),⁴² with a relatively high rate of IgE-mediated anaphylaxis elicited by succinylcholine and rocuronium compared with other muscle relaxant agents.⁴³

Volatile anesthetic agents are not generally considered histamine-releasing drugs,⁴⁴ and a recent study supports the notion that sevoflurane can inhibit MC activation.⁴⁵ Another *in vitro* study reported that MCs isolated from different anatomic sites and different donors showed a remarkable degree of heterogeneity in releasing histamine in response to ketamine, propofol, and thiopental. These drugs also did not induce *de novo* synthesis of prostaglandin (PG) D₂ and leukotriene C₄ from lung and skin MCs.²²

It is generally believed that most opioids are able to directly induce histamine release, a property thought to be responsible for many reactions that occur more frequently than IgE-mediated reactions to these drugs.⁴⁶ However, there are reports of *in vitro* studies that found that fentanyl did not induce either histamine or tryptase release.^{47,48} Furthermore, one *in vivo* microdialysis study in human skin tested codeine, pethidine, fentanyl, sufentanil, remifentanyl, buprenorphine, and naloxone and reported that only codeine and pethidine induced MC activation.⁴⁹ Finally, it is also reported that the vasodilatation and hypotension produced by opioids is less prominent with fentanyl and sufentanil than with morphine because fentanyl and sufentanil did not induce release of histamine during their use.⁵⁰

There is little information on local anesthetic-related histamine release, but lidocaine (and other amide-type local anesthetics) use rarely leads to an allergic response and has been shown *in vitro* to downregulate the immune response, possibly through T-cell suppression and increased intracellular MC calcium concentrations.^{51,52} The incidence of allergic reactions to local anesthetics in the general population is also low,⁵³ and a true IgE-mediated allergy to local anesthetics among suspicious cases after allergologic work-up is described as less than 1%.⁵⁴ In addition, after introduction of amide local anesthetics in the 1940s, the number of cases of allergy to local anesthetics decreased.⁵³ A recent review¹⁹ highlighted the limited information available about the administration of colloid fluid therapy in patients with mastocytosis and recommended gelatin and hydroxyethyl starch, if needed. Randomized controlled trials or meta-analyses regarding the use of anesthetics in mastocytosis are not available. In general, recommendations are based on the avoidance of histamine-releasing drugs, as well as the clinical experience published.^{19,34,36,55,56}

It is not routinely recommended to perform skin tests to anesthetic drugs in patients with mastocytosis before an anesthetic procedure.^{18,19,34,36,57} However, a complete allergy

TABLE II. Clinical characteristics of adult cases (n = 676) grouped according to the presence or not of perianesthetic MC mediator release–associated symptoms³⁴

	Asymptomatic (n = 665)	Symptomatic (n = 11)	P value
Female sex	380 (57%)	6 (54%)	NS
Type of anesthesia			
General	62 (9%)	4 (36%)	.02
Sedation	65 (10%)	2 (18%)	NS
Epidural	74 (11%)	2 (18%)	NS
Local	511 (77%)	4 (36%)	.005
Major surgery	60 (9%)	5 (45%)	<.001
PAT given 1 h before anesthesia	578 (87%)	5 (45%)	.002
H ₁ -antihistamines	567 (85%)	4 (36%)	<.001
H ₂ -antihistamines	566 (85%)	4 (36%)	<.001
Corticosteroids	67 (10%)	2 (18%)	NS
Montelukast	16 (2%)	0 (0%)	NS
Benzodiazepines	494 (74%)	3 (27%)	.002
Anaphylaxis	258 (39%)	8 (72%)	.03
Anaphylaxis the year before	96 (14%)	5 (45%)	.02
Idiopathic	87 (13%)	4 (36%)	.048
Insect sting	116 (17%)	3 (27%)	NS
Drugs	86 (13%)	4 (36%)	.046
Foods	19 (3%)	0 (0%)	NS
<i>Anisakis simplex</i>	12 (2%)	0 (0%)	NS
Physical stimuli	5 (1%)*	0 (0%)	NS
Aspirin score			
I	22 (3%)	3 (27%)	.006
II	541 (81%)	8 (73%)	NS
III	100 (15%)	0 (0%)	NS
IV	2 (0.3%)	0 (0%)	NS

Results are expressed as numbers (percentages) of cases. Permission granted for reprint from Karger Publishers.

NS, Not statistically significant (*P* > .05); PAT, prophylactic antimediator therapy.

*Friction of skin mastocytoma.

work-up is recommended, with a focus on use of drugs that might have elicited symptoms caused by MC mediator release previously or in patients who presented with prior uninvestigated perioperative anaphylaxis and/or MC mediator–related symptoms.^{18,34,36} A serum tryptase determination can support the diagnosis of perioperative anaphylaxis. In patients who experience perianesthetic mediator–related symptoms, serum should be obtained 15 to 60 minutes after the acute episode, as well as 24 or more hours after resolution of the episode, for a baseline serum tryptase value. If the acute tryptase value exceeds 120% plus 2 ng/mL of the baseline level, a diagnosis of anaphylaxis is supported.⁵⁸ In addition, serum basal tryptase determination before surgery is recommended by some authors in the belief that it reflects MC burden and thus the increased possibility of a reaction.^{18,34–37,57} However, in one study,³⁴ serum basal tryptase levels determined in the year before patients underwent anesthesia did not reliably predict the occurrence of a perianesthetic episode of MC mediator release–related episodes.

Key points in this section are listed in [Box 1](#).

ASPIRIN AND NONSTEROIDAL ANTI-INFLAMMATORY DRUG REACTIONS

It is common to hear from patients referred with newly diagnosed SM that they have been advised by their physician to “avoid aspirin and nonsteroidal anti-inflammatory medications.”

Box 1. Adverse drug reactions during anesthesia

- Patients at greater risk of adverse reactions during anesthesia are those with a history of anaphylaxis, those who have undergone major surgeries, and those who have been exposed to general anesthesia.
- The benefit of administration of prophylactic antimediator therapy before anesthetic procedures has not been thoroughly evaluated, and there is no consensus about their routine administration. Premedication is recommended in patients with previous perioperative anaphylaxis in need of future general anesthesia if the culprit agent has not been identified.
- A reasonable approach is to choose those drugs with low capacity to elicit MC degranulation in each pharmacologic group (eg, aminosteroids, neuromuscular blockers, short-acting synthetic opioids, and amide derivatives among local anesthetics) and to use drugs with known tolerance by individual patients.
- After perioperative anaphylaxis, obtain a serum tryptase value 15 to 60 minutes after the acute episode and 24 or more hours after resolution of the episode.
- A complete allergic work-up before anesthesia is recommended for patients with mastocytosis who have experienced perioperative mediator-related symptoms in the past. However, routine preoperative skin testing with drugs to be used is not recommended.

The reflex admonition from their well-meaning doctors is undeserved. It possibly derives from several interrelated clinical observations.

First, aspirin is also reported to exacerbate chronic urticaria and angioedema, disorders that involve MC activation/degranulation, in 21% to 41% of cases.⁵⁹

Second, a subset of asthmatic patients, those with aspirin-exacerbated rhinosinusitis and asthma, can have acute severe worsening of symptoms and, in fact, might die after administration of COX-1 inhibitors, such as aspirin.^{56,60–62} Moreover, mediators derived from MCs are released during these reactions.^{63,64}

Third, a second aspirin-related respiratory condition, aspirin-sensitive rhinosinusitis, can occur independently of aspirin-sensitive asthma in some patients.^{59,65}

Fourth, although the prevalence of atopy in patients with mastocytosis does not differ from that of the general population,^{66,67} there is concern that patients with mastocytosis, particularly adults with ISM without skin involvement, have an increased risk of anaphylaxis triggered by a variety of agents.^{7,9,13,68}

Fifth, acetylsalicylic acid has been implicated as a cofactor in augmenting anaphylaxis in patients with food-associated exercise-dependent systemic anaphylaxis,^{69,70} and in a patient with ISM with oral allergy syndrome to carrots, in whom flushing, dizziness, and respiratory distress occurred only after prior exposure to acetylsalicylic acid 60 minutes before consumption of carrots but not by ingestion of carrots alone.⁷¹ In such cases aspirin can act to increase gastrointestinal permeability, thereby enhancing systemic distribution of ingested allergens.⁶⁹

Identification of increased levels of 11β-PGF₂α in the urine of patients with SM have helped to establish that PGs can contribute to symptoms in patients with this condition.^{72–75} Up to 10% of patients with SM have sudden worsening of symptoms after receiving aspirin,^{76–78} but to date, we know of no aspirin-

triggered fatality in a patient with SM. In addition, production of the vasoconstrictor prostanoid thromboxane (TX) A₂ is increased in patients with SM, as reflected by increased serum levels of its inactive metabolite TXB₂ and urinary excretion of the TXB₂ metabolite 11-dehydro-TXB₂. TX formation was highly correlated with urinary excretion of major urinary metabolites of histamine and PGD₂.⁷⁹

Aspirin is a useful agent to control mastocytosis symptoms in some patients. Aspirin is inexpensive, easily obtained, and available in a variety of dosage forms, including enteric-coated pills and chewable tablets. Successful use of aspirin in patients with mastocytosis is documented in several reports, although adverse reactions do occur.⁸⁰⁻⁸⁴ In an early report of patients with mastocytosis lacking skin lesions, attacks of flushing were associated with marked increases in levels of urinary PGD₂ metabolites, and doses of aspirin in the range of 3.9 to 5.2 g/d were used to prevent these episodes. Among these patients, about 10% reported severe attacks of hypotension with aspirin in doses as low as 40 mg, as well as with other nonsteroidal anti-inflammatory drugs (NSAIDs).⁷⁸ In a case report of a patient with CM and SM with a history of extreme sensitivity to indomethacin, gradual aspirin dosing up to 975 mg every 6 hours combined with H1 and H2 blockade successfully controlled hypotensive and syncopal attacks.⁸² Aspirin treatment at a dose of 750 mg/d was successfully added to a failed program of terfenadine and cimetidine and oral disodium cromoglycate in one other SM case.⁸⁴ Treatment with aspirin, 160 mg twice daily for 4 days, is reported to suppress TX production in patients with mastocytosis.⁷⁹

Aspirin-intolerant patients with SM can be desensitized to aspirin, although this procedure can take several days in an intensive care setting and can be associated with acute release of vasoactive peptides, including calcitonin gene-related peptide, histamine, and PGD₂, which contribute to hypotension.^{80,82} Successful desensitization has been described, and the reader is referred to these publications for details.^{35,80-82,85} Desensitization should always be performed in an intensive care setting for any patient that has experienced a hypotensive or generalized adverse reaction to aspirin. After desensitization, daily dosing with aspirin is required to maintain a tolerant status and to continuously inhibit COX activity and PGD₂ production.

As with aspirin, there is a reluctance to prescribe NSAIDs to patients with SM. The possible reasons for this can be derived from literature reports of adverse reactions to this class of drug in general. First, NSAIDs are among the most frequently implicated drugs in cases of medication-triggered anaphylaxis.^{86,87} Second, NSAIDs are accountable for up to one quarter of adverse drug reactions with clinical symptoms of bronchial asthma, rhinosinusitis, anaphylaxis, or urticaria and several other late cutaneous reactions.⁸⁸ In one series of 212 patients with mastocytosis (116 adults and 96 children), 14% of adults but only 2% of children reacted to aspirin or other NSAIDs (pyrazolone, diclofenac, ibuprofen, and naproxen). Symptoms consisted of anaphylaxis, followed by urticaria, asthma, flushing, and angioedema.⁸⁹ However, when tryptase levels were assessed in 284 patients with a history of NSAID hypersensitivity, only 9.2% were found to have a basal tryptase value of greater than 10 ng/mL. Basal tryptase values of greater than 20 ng/mL were associated with severe anaphylaxis only in patients with venom allergy but not in NSAID-hypersensitive patients.⁹⁰ In this series a diagnosis of ISM was possible in only 3 patients. Based on this finding and the fact that the severity of hypersensitivity reactions

Box 2. Aspirin and nonsteroidal anti-inflammatory drug reactions

- Up to 10% of patients with SM can experience aspirin-triggered adverse reactions. The adverse response rate to other NSAIDs might be less.
- Patients who tolerate aspirin and other NSAIDs before a diagnosis of SM generally continue to tolerate these medications.
- Among children with mastocytosis, the risk of adverse reactions appears to be lower than in adults, although more information is needed.
- For patients who have not obtained symptom control with antihistamines, 5-lipoxygenase inhibitors, leukotriene C/D₄ receptor blockers, and other agents, aspirin pharmacotherapy might help control SM-related symptoms associated with increased production of PGD₂, although their use must be instituted with caution. Fortunately, many patients with SM can be controlled with modest doses of aspirin, making dosing with aspirin relatively simple and well tolerated.
- For those patients with mastocytosis requiring aspirin who have responded adversely to this medication, desensitization is possible in an intensive care setting for patients who have experienced a hypotensive or generalized adverse reaction.

was not increased in patients with increased tryptase values, avoiding NSAIDs in SM might be unwarranted and best approached on a case-by-case basis.

Key points in this section are listed in [Box 2](#).

ADVERSE REACTIONS TO HYMENOPTERA VENOM IMMUNOTHERAPY

Published observations show an association between Hymenoptera venom allergy (HVA) and mastocytosis.⁹¹ Hymenoptera stings appear to represent the most common trigger of anaphylaxis in subjects with clonal MC disorders.^{7,9,92}

The prevalence of HVA in the adult general population in Western countries is about 3%, whereas the prevalence of insect venom allergy in patients with any form of mastocytosis is higher and estimated to be 20% to 30%. Furthermore, patients with SM and HVA have an increased risk of severe systemic reactions compared with patients without SM, as described in case reports and small series studies of patients with HVA. Additionally, the prevalence of SM in the general population is 1.0 to 1.3/10,000, and the prevalence of SM in patients with HVA is significantly higher. The first report of the use of bone marrow evaluations of patients with HVA and increased tryptase levels, including detection of minor criteria for mastocytosis, reported a percentage of clonal mast cell disease (CMD) as high as 7.9%.⁹¹

The association between HVA and CMD was initially described mainly in patients with urticaria pigmentosa,^{17,93,94} but it is now established that the majority of patients with HVA and SM are given a diagnosis of SM lacking skin lesions that is considered bone marrow mastocytosis.^{9,13,68,91,95,96}

Patients with HVA and SM have some features different from those with SM only that occur in patients without Hymenoptera-induced anaphylaxis. Male sex is prevalent, and there is usually a low occurrence of mediator-related symptoms, a lower probability of having MC aggregates on bone marrow examination, and lower median baseline serum tryptase levels.

Moreover, they systematically show a *KIT* mutation restricted to MCs and not expressed in the remaining myeloid lineages or lymphoid cells, as happens in patients with other subtypes of mastocytosis.¹³ Recently, some authors reported that the presence of hypotension without erythema, angioedema, or both is highly predictive of clonal MCD, irrespective of normal tryptase levels.⁹⁷

Venom immunotherapy (VIT) is recognized as a life-saving treatment for patients with HVA. After some debate, mainly because of safety concerns, it is now generally accepted that VIT is safe and effective in patients with HVA and SM.^{98,99} Recommendations have now been provided for the use of VIT in patients with SM and HVA based on a large data set.¹⁰⁰ This study confirmed that VIT is an effective and safe therapeutic option and that this therapy is well tolerated, although a slightly higher number of adverse events was seen with a rush-modified induction regimen. Omalizumab (anti-IgE antibody) has been used as an adjunctive treatment in patients with mastocytosis for both symptom improvement and to dampen adverse effects caused by VIT.^{101,102} Concomitant use of omalizumab assists in induction and maintenance of VIT, and the drug can be terminated after maintenance therapy is achieved. Thus, despite lack of achieving statistical significance, it would appear reasonable to suggest a less aggressive induction in patients with SM.

Immunotherapy confers a reasonable protection in the majority of patients, as observed in patients without SM and in patients receiving an extended maintenance regimen. However, for patients with HVA and SM not fully protected at field re-stings, an increase in the maintenance dose could be recommended. Before increasing the dose, it is mandatory to be sure that the diagnosis is correct and to exclude a new sensitization. Recently, it has been reported that there is a diagnostic advantage in the use of recombinant allergens with a lower-end assay cutoff of 0.1 kU_A/L for the diagnosis of patients with low or undetectable specific IgE levels to venom extract in general and especially for patients with increased baseline serum tryptase levels, mastocytosis, or both.¹⁰³

In general, clinical observations appear to confirm that after VIT lasting 3 to 5 years, many patients with mild-to-moderate anaphylactic symptoms remain protected after VIT discontinuation independent of positive skin test responses. However, lifelong treatment should be considered in high-risk patients.¹⁰⁴ This is because case reports indicate that patients with mastocytosis and HVA, who were protected during VIT, can have very severe reactions after VIT discontinuation, and 2 fatalities have been described in 2 patients who were stung after stopping VIT. One death occurred 4 years after a 5-year course of VIT and the other occurred 6 months after a 2.5-year course of VIT.¹⁰⁵ Therefore, in patients with mastocytosis, some recommend VIT to be lifelong. To better improve the compliance of patients who have to continue the lifelong injections, a 3- to 4-month extended interval between injections can be considered because this maintenance schedule, adopted after 5 years of immunotherapy, appears safe and effective.¹⁰⁶

Key points in this section are listed in [Box 3](#).

ADVERSE REACTIONS TO ANTIBIOTICS AND OTHER DRUGS

Drugs are known to induce anaphylaxis in some patients with mastocytosis, particularly β -lactams but also other antibiotics,

Box 3. Adverse reactions to Hymenoptera venom immunotherapy

- HVA represents the most common cause of anaphylaxis in patients with mastocytosis.
- VIT is recommended for patients with mastocytosis and HVA.
- A less aggressive induction of HVA is recommended for patients with SM to reduce the risk of side effects. Alternatively, omalizumab can be used to help achieve induction and maintenance of VIT.
- Lifelong VIT should be considered.
- VIT in patients with mastocytosis is accompanied by a greater frequency of side effects, and thus special precautions must be taken during the build-up phase of the therapy.
- VIT can reduce systemic reactions, although to a lesser extent compared with in the general population with HVA. Patients with SM should be warned that the efficacy of VIT might not be fully protective, and thus they should carry 2 epinephrine autoinjectors.

such as aminoglycosides or streptomycin. Other drugs reported in patient histories to elicit adverse reactions are NSAIDs, radio contrast medium (RCM), phenylephrine, codeine, and local and general anesthesia.^{7,9} However, there has been no formal confirmatory testing based on either the presence of positive skin test or provocation test results described in patients with mastocytosis for most of these agents.

The frequency of underlying CMD in patients with drug hypersensitivity is unknown. Only a few studies have tried to investigate undetected SM in association with drug reactions. One study determined the frequency of CMD in patients with food- and drug-induced anaphylaxis by performing bone marrow biopsies in patients (6.6%) with increased serum tryptase levels (>11.4 ng/mL). Only one of 5 bone marrow-tested patients was given a diagnosis of SM. The authors observe that the severity of reactions was significantly greater in patients with mastocytosis and drug hypersensitivity.⁶⁸

The prevalence of immediate hypersensitivity reactions (urticaria and anaphylaxis) in adults with SM is not known but appears to be less than that to HVA and might be slightly increased or similar compared with that of the general population.¹⁶ There is no evidence that the prevalence of nonimmediate reactions (exanthems) is increased. One case report documents a significant increase in serum tryptase levels to 180 ng/mL after a penicillin skin test in a woman with increased levels of basal tryptase (17.3 ng/mL) and clinical symptoms of pruritus, syncope, and hypotension with β -lactam ingestion and negative serum test results, which makes her suspect for an underlying clonal disease.¹⁰⁷

In general, for patients, medications previously and continuously tolerated by patients are allowed. In contrast, in patients with a history of an antibiotic reaction, the culprit drugs and those belonging to the same antibiotic family should be avoided until ruled out by allergy testing. Generally, after a drug hypersensitivity reaction, allergy testing is recommended. Such patients might consider wearing a Medic-Alert bracelet or similar device. However, it should be noted that skin and laboratory tests to drugs often have a low sensitivity and that a negative test result does not necessarily indicate tolerance.¹⁰⁸ A drug provocation test should

Box 4. Adverse reactions to antibiotics and other drugs

- Patients with mastocytosis with drug reactions should undergo appropriate allergy testing if the drug is to be readministered.
- It is reasonable to recommend that patients take medications previously and continuously tolerated.
- In children with MIS, the most common cause of anaphylaxis is idiopathic.
- The risk of anaphylaxis to drugs in children might be greater in those with MIS and extensive skin involvement and high serum tryptase levels.

be considered, and the risk of inducing a more severe reaction in a patient with SM compared with a patient without SM has to be balanced against the benefit of possible unnecessary avoidance. Thus such testing should be done with slow dose increments, emergency preparedness, and a team experienced with anaphylaxis treatment. Finally, it is important to refer all patients with adverse reactions to drugs to an allergy specialist and especially for patients with mastocytosis for appropriate counseling and, if necessary, testing (eg, skin testing for penicillin allergy or provocation testing in the case of most drugs) at a specialized center where testing can be performed under close supervision.

Limited data are available regarding the safety of drugs in children with mastocytosis. In one study 133 children with various forms of MIS were evaluated. Reactions to medications were registered in 12 patients, most of which had a maculopapular pattern of CM. Six of these reactions were due to β -lactam antibiotics, 3 to acetaminophen, and 2 to the measles, mumps, and rubella (MMR) vaccine.¹⁰⁹ In another study 111 children with MIS, increased basal serum tryptase levels, and extensive cutaneous involvement were identified as predictors for severe MC mediator release symptoms. However, only 4 had immediate hypersensitivity reactions to drugs with pruritus only ($n = 1$) or together with hives ($n = 2$) or without angioedema ($n = 1$). The culprit drugs were dipyrone and diclofenac, ibuprofen, and a polivitaminic complex.¹⁰

Key points in this section are listed in [Box 4](#).

ADVERSE REACTIONS TO mAbs

Downregulation of MC activation and survival might be warranted in the treatment of patients with mastocytosis by targeting uniquely expressed surface receptors with mAbs to control the symptoms and survival of clonal MCs.¹¹⁰ Surface receptors, such as TNF-related apoptosis-inducing ligand receptor (a death receptor expressed on human MCs), CD300a, and sialic acid-binding immunoglobulin-like lectin 8, have potential downregulatory properties on MC activation and survival *in vivo*. A group of proapoptotic factors, such as BH3 proteins, have also been described to modulate MC survival. Chimeric and humanized mAbs have also been associated with local and systemic hypersensitivity reactions,¹¹¹ including IgE-mediated¹¹² and non-IgE-mediated anaphylaxis in patients with a number of diverse disorders, but their potential effect on patients with CMD carrying *KIT* mutations has not been studied. Reactions in a more general population are more frequent with chimeric antibodies, such as rituximab, but are also seen with

humanized mAbs, such as omalizumab, and are associated with repeated exposures, such as for infliximab.

Because Fc ϵ RI receptors are expressed on MCs¹¹³ and these cells can be activated through cross-linking of bound IgE with specific antigens, IgE removal has been used to help prevent specific MC activation. Omalizumab, a humanized anti-IgE murine mAb initially used for severe asthma and now US Food and Drug Administration (FDA) approved for chronic idiopathic urticaria and angioedema, has been used in mastocytosis to control MC activation in patients with spontaneous and antigen-induced anaphylaxis.¹¹⁴ Although 0.09% to 0.2% of patients with asthma using omalizumab are reported to experience anaphylaxis, there are, as of the writing of this report, no studies focusing on reactions to omalizumab in those with CMD.

A recently described subgroup of patients with ISM with or without MIS presenting with Hymenoptera-induced anaphylaxis has been treated with VIT.^{99,100} The widespread use of VIT has been hampered by severe anaphylactic reactions during the build-up phase and maintenance phase, and omalizumab has been reported to prevent these reactions in allergic subjects.¹¹⁵ Furthermore, a series of anecdotal reports have now supported the safety and efficacy of omalizumab in patients with mastocytosis.¹¹⁶

An initial report in 2008^{117,118} of a man with ISM who presented with near-fatal anaphylaxis after a bee sting and required omalizumab to reach maintenance immunotherapy has illustrated some of the current knowledge regarding its use. The patient required 300 mg of omalizumab every 4 weeks to achieve maintenance without anaphylactic symptoms, and when the dose was reduced to 150 mg, the symptoms of anaphylaxis recurred. Once back on 300 mg the patient's symptoms resolved during maintenance immunotherapy. The patient was stabilized at 300 mg every 28 days without further anaphylaxis during maintenance injections, and the tryptase level of 41.7 ng/mL decreased after 1 year to 18.3 ng/mL. The decrease in tryptase levels has also been observed in other clinical reports¹¹⁹ and might be consistent with an off-target effect of omalizumab on MC survival, although a tryptase level decrease was not observed in patients who were protected against spontaneous anaphylaxis.¹¹⁴

Only local side effects have been reported at the sites of injections of omalizumab, but no systemic symptoms^{120,121} have yet been reported. There is 1 report of a patient with CMD and anaphylaxis to Hymenoptera venom but undetectable specific IgE levels who was treated with omalizumab and was protected against Hymenoptera field anaphylaxis.¹¹⁸ Similarly, a woman with mastocytosis and unprovoked anaphylaxis¹¹⁹ was protected by omalizumab, with evidence of lack of recurrence of anaphylaxis and with decreased tryptase levels.

Daclizumab and basiliximab are IL-2 receptor-directed mAbs that have been used in SM.¹²² There have been no reported side effects. Similarly, gemtuzumab ozogamicin is a fusion protein toxin that targets CD33 and has proved successful in patients with acute myeloid leukemia. Its use in SM is at the preclinical stage. Exposure of the HMC-1 cell line to gemtuzumab has resulted in reduced viability of CD33⁺ MCs. It is noteworthy that administration of gemtuzumab has been associated with rare but severe hepatic veno-occlusive disease in patients with hematologic malignancies. Few cases of SM have been associated with lymphoma. In one case of a 74-year-old man with diffuse large B-cell lymphoma with SM, treatment with rituximab¹²³ did not

Box 5. Adverse reactions to mAbs

- An increase in the use of mAbs is predicted in patients with CMD to target MC surface molecules implicated in MC activation and proliferation.
- Omalizumab has been found to be effective in decreasing unprovoked anaphylaxis in patients with mastocytosis and in particular in patients with Hymenoptera-induced anaphylaxis.
- There is no evidence of an increase in adverse reactions to mAbs in patients with CMD in contrast to other populations.

produce any side effects but had no effect on the mastocytosis. Although there are no published reports of the use of infliximab or other anti-TNF blockers in patients with CMD, 2 patients at the Brigham and Women's Hospital Mastocytosis Center with rheumatoid arthritis and ankylosing spondylitis have been treated with TNF- α blockers without significant side effects and with improvement of their underlying connective tissue disorder and good control of MC mediator-related symptoms. Thus mAbs have been used in patients with mastocytosis with few side effects. This section was done using PubMed by matching mAbs and mastocytosis and using the specific mAbs omalizumab, rituximab, infliximab, and etanercept and other TNF- α blockers from 1998 to 2016.

The key points in this section are listed in [Box 5](#).

HYPERSENSITIVITY TO RCMs

RCMs do not appear to be common triggers of anaphylaxis in patients with CMD, despite intravascular injection of high volumes and concentrations of RCMs. Theoretically, this might be associated with distribution of RCMs preferentially to rapidly infused organs, such as the liver, kidney, or brain, with a relatively low number of MCs there compared with the skin or bone marrow. However, there are a few reports on the concurrence of SM in patients with RCM hypersensitivity reactions and on RCM hypersensitivity in patients with SM. In the Medline database, we found in total 6 cases that have been published with anaphylaxis triggered by RCMs in adult patients with SM in case reports, case series or studies over the last 30 years.^{7,105,123-125}

In a large multicenter study that included 122 patients with immediate RCM hypersensitivity, none of the patients had the diagnosis of SM.¹²⁶ In an Italian study of 86 adult patients with severe drug hypersensitivity, RCM was responsible for anaphylaxis, with loss of consciousness in 1 patient with a basal tryptase level of 20.1 ng/mL, but CMD was excluded based on results of bone marrow biopsy and analysis for the D816V *KIT* mutation.⁶⁸ In 83 adults with MC mediator release episodes but without overt MIS, RCM was not among reported triggers.⁹⁵ In 3 studies that analyzed the frequency of anaphylaxis in patients with mastocytosis taken together, RCM was the trigger in 2 of 321 adults (108 with anaphylaxis) and none of 93 children (7 with anaphylaxis).^{7,9,12}

Mastocytosis has not been reported as an underlying disease in patients with fatal RCM-induced anaphylaxis. Overall, it remains questionable whether there is a greater risk of anaphylaxis specifically to RCM in patients with mastocytosis compared with the general population.

Box 6. Hypersensitivity to RCMs

- RCMs are not common triggers of anaphylaxis in patients with mastocytosis.
- It remains questionable whether there is a greater risk of anaphylaxis to RCMs in patients with mastocytosis compared with the general population.
- As with all patients with previous anaphylaxis to RCMs, patients with mastocytosis should be allergy tested by using skin prick tests with undiluted RCMs and intradermal tests with 1:10 diluted RCMs.
- In those few patients (approximately 10% to 25%) with positive skin test results, an RCM with negative skin test results can be identified and used, whereas in the others the culprit RCM structure should be avoided for further RCM examinations.
- Emergency preparedness and resuscitation facilities should be nearby before administering RCMs to adults with mastocytosis.

A previous hypersensitivity reaction to RCM carries a risk for new reactions on re-exposure.¹²⁷ In patients with RCM-induced anaphylaxis, no specific recommendations for patients with mastocytosis have been proposed.¹²⁷ Independent of mastocytosis, if a patient with a previous reaction needs another contrasted examination, the culprit RCM should be avoided.¹²⁷ Magnet resonance imaging contrast agents can be used because they are structurally different and show no cross-reactivity to RCM.

Skin tests with RCM using undiluted RCM for skin prick tests and 1:10 diluted RCM for intradermal tests have been recommended but will only produce positive results in a minority (approximately 10% to 25%) of patients with immediate reactions (anaphylaxis) and 30% to 70% of patients with nonimmediate reactions (exanthemas) where the clinical pictures were typical for drug-induced hypersensitivity reactions.¹²⁷ If patients have a positive skin test reaction to the culprit, cross-reactivity to other RCMs is common and appears to be structure dependent.¹²⁸ Testing should best be done within 6 months after the initial reaction.¹²⁶

Thus the recommendation is that in patients with a previous reaction to RCM and positive skin test result, a skin test-negative product should be identified and used. However, the predictive value for the selection of an alternative RCM based on skin test results still has to be defined. This might be limited to those patients with positive skin test responses. The negative predictive value of reapplication of RCM in combination with skin tests has been reported to be high in one study.¹²⁹

In patients with a negative skin test result or in whom skin tests are not possible, it is common practice to use premedication, although this is controversially discussed, and there is a risk of breakthrough reactions.¹³⁰ Corticosteroids (50 mg of prednisone 13 hours, 7 hours, and 1 hour before the procedure) and H₁-antihistamines (50 mg of diphenhydramine 1 hour before the procedure) with or without H₂-antihistamines are most frequently recommended.¹²⁷ However, the value and need of premedication in patients with mastocytosis is unproved and has to be further established by more data.

Key points in this section are listed in [Box 6](#).

ADVERSE REACTIONS TO VACCINES

Adverse vaccine reactions in general pediatrics

Vaccines have contributed to an overall increased standard of living by reducing morbidity and mortality caused by infectious diseases.¹³¹ The incidence of adverse reactions to vaccines in the general US population ranges from 3.0% to 6.3%, depending on the particular vaccine. Local injection-site reactions and mild constitutional symptoms, such as fever, are common. Anaphylactic reactions are rare and estimated to occur at a rate of 1 per million doses.¹³² IgE-mediated reactions to vaccines have been reported as the result of additives and residual vaccine components, such as gelatin, yeast, latex, neomycin, thimerosal, and casein.¹³³⁻¹³⁷ In some reactions the gelatin stabilizer in the MMR and Japanese encephalitis vaccines was thought to be the culprit.¹³⁸⁻¹⁴¹ When the gelatin was removed from the vaccine in Japan and Germany, there was a decrease in the incidence of adverse reactions.^{142,143} Anaphylactic and nonanaphylactic reactions to vaccines should be evaluated and, when appropriate, skin tests should be performed to the vaccine or components to rule out an IgE-mediated sensitivity and contraindications for future doses. Patients with egg allergy can receive influenza or yellow fever vaccines under standard conditions because studies have demonstrated a low rate of reactions.¹⁴⁴⁻¹⁴⁸ However, in patients allergic to egg proteins, the vaccine should be administered in a setting in which anaphylaxis can be properly diagnosed and treated.

Adverse vaccine reactions in patients with mastocytosis

Patients with mastocytosis in general have an increased incidence of adverse reactions to exogenous agents, although to a lesser extent in children. This might be due to exposure in other drug categories, but the majority of vaccines are given during infancy and childhood. Children with mastocytosis should be given mandatory vaccinations according to the general vaccination schedule used in the United States and Europe. In 2 studies routine vaccinations were considered a cause of anaphylaxis or other symptoms caused by MC activation, although no specific data on the incidence of vaccination-induced anaphylaxis were reported.^{7,10}

In addition to anaphylaxis, vaccinations can potentially induce activation or exacerbation of mediator-derived symptoms, such as generalized flushing, pruritus, urticaria/angioedema, bullous lesions, or gastrointestinal symptoms, in children with mastocytosis. One case report described an extensive bullous reaction after vaccine administration in a 5-month-old child with diffuse cutaneous mastocytosis (DCM).¹⁴⁹ In this report the first administration of a multivalent vaccine was proposed as the triggering factor of MC activation, which resulted in a generalized skin eruption. In addition, 2 case reports raised the question of whether vaccine administration might be associated with onset of mastocytosis.^{150,151} Both reports described the development of a mastocytoma at the site where hepatitis B vaccine had been injected.

Uncertainty about the relationship between vaccines and mastocytosis often generates concerns in both parents and health care providers at the time of administration of mandatory vaccines in children with this disease. In a recent study 4 cases of an adverse reaction after the first dose of hexavalent vaccine

Box 7. Adverse reactions to vaccines

- Although the rate of reaction is slightly greater in patients with mastocytosis, vaccines should be administered on the recommended schedule.
- Patients with egg allergy can receive egg protein-containing vaccines. If a more cautious approach is needed based on disease severity or previous reaction without an identified antigen, both skin testing when possible and administration of graded doses might be warranted.
- In the majority of cases, reactions are localized to the skin.
- Single-vaccine regimens can be considered in patients with DCM and extensive skin involvement.
- A postvaccination waiting period of 2 hours is recommended, with instructions given to the parents regarding when to seek additional medical care.

were reported in a population of 72 children with mastocytosis.¹⁵² Reactions occurred in patients with all 3 major variants of pediatric mastocytosis, maculopapular CM, mastocytoma, and DCM. The rate of reactions to vaccinations in patients with mastocytosis (4 cases per 634 vaccine doses) was greater than that reported in the general population (2.3 cases per 10,000 doses). Although there is no conclusive evidence that reactions were due to MC activation induced by vaccine components, the close time relationship between the onset of clinical manifestations and vaccine administration makes the procedure a likely trigger of the reactions. The most frequent reaction was generalized urticaria, appearing 2 to 4 hours after vaccine administration. The more severe reaction, characterized by bullous eruption and bronchospasm, occurred in 1 child with DCM and high serum tryptase levels. No systemic reactions, including severe hypotension or anaphylaxis, were recorded in this study. Notably, all reactions occurred at the first administration of a hexavalent vaccine preparation, usually injected at 3 months, and no further reaction was detected at subsequent boosters of the same vaccine. None of the 4 children had reactions to other mandatory vaccines, including a trivalent formulation MMR, meningococcus, or varicella.

There are no data on the tolerability of egg-containing vaccines, such as influenza or yellow fever vaccine, in patients with egg allergy and underlying mastocytosis. Thus if a cautious approach is indicated by disease severity or a previous reaction along with skin testing, when possible, administration of graded doses in case of positive skin test reactions might be warranted. This testing and administration of the vaccine should be performed in a center with experience in the treatment of anaphylaxis.

Taken together, published data appear to indicate that children with mastocytosis have a slightly higher rate of adverse reactions to first administration of vaccine than that of general population. However, these reactions are mild and transient and do not recur on booster injections. The occurrence of reactions only after a hexavalent vaccine administration suggests that injection of single vaccines rather than polyvalent formulations can be considered in children with DCM. In any case administration of the first dose of vaccine to children with mastocytosis should be done in a controlled clinical setting with monitoring of the patients for 1 to 2 hours after injection, with more caution shown

in patients with DCM. It might be advisable to give parents an emergency management plan containing instructions for recognition of symptoms and warning signals requiring report of the child to the nearest emergency department and/or use of epinephrine in children with previous anaphylaxis.

Although there are no data on the prevalence of adverse reactions in adults with mastocytosis, such as influenza, hepatitis B, or travel-related vaccinations, there is a general consensus of experts that mastocytosis is not a contraindication to vaccinations in adults.¹⁵³

Key points in this section are listed in [Box 7](#).

SUMMARY

Mastocytosis is associated with a greater risk for anaphylaxis and a greater severity of anaphylaxis compared with those seen in patients without mastocytosis.⁸ Triggers of anaphylaxis in patients with mastocytosis are predominantly Hymenoptera venoms, but also anaphylaxis to drugs, food, and idiopathic anaphylaxis can occur. The risk of anaphylaxis to drugs and biologicals is regarded as an area of concern and investigation.

Patients with mastocytosis react to the same drugs as those without SM, such as β -lactam antibiotics, NSAIDs, RCMs, and others. In children with mastocytosis, drug hypersensitivity is uncommon. If there is no history of a previous hypersensitivity reaction, there is no need to withhold any medications from patients with mastocytosis, and precautionary measures discussed in this article are regarded. We recommend referring all patients with drug hypersensitivity reactions to an allergy specialist, especially patients with mastocytosis, for appropriate counseling and, if necessary, specific skin testing at a comprehensive center, where testing can be performed under close supervision.

Perioperative anaphylaxis can occur in patients with mastocytosis, being reported more commonly in adults compared with children. Approximately 0.4% of adults with mastocytosis can have anaphylaxis. The anesthetic management of patients with mastocytosis requires a thorough understanding of mastocytosis, a detailed patient history, avoidance of previously nontolerated drugs, and meticulous preparation to treat possible adverse events during anesthetics and RCM administration. When needed, drugs, such as opioids and muscle relaxants, can be used, especially when there is no history of previous adverse reaction. If available, drugs with lower MC-releasing properties *in vitro* can be selected by the anesthetist, although clinical evidence for this approach is lacking. Baseline serum tryptase levels and peak tryptase levels taken 30 to 120 minutes after perianesthetic symptoms are valuable for the diagnosis of intraoperative anaphylaxis. Routine preoperative drug testing is not recommended. However, after an anaphylactic reaction, skin testing and determination of specific IgE levels (available only for few allergens) are recommended and a drug challenge test might be considered. In children with mastocytosis, routine prophylactic antimediator therapy should be considered on a case-by-case basis. Chronic antimediator therapy should not be discontinued. In adults prophylactic antimediator therapy based on antihistamines with or without benzodiazepines 1 hour before anesthesia, as well as corticosteroids before general anesthesia, reduced the frequency of perianesthetic mediators related symptoms in one study and should be considered especially in patients at risk. Patients at greater risk are those who had previously presented with anaphylaxis

and are undergoing major surgery and those receiving general anesthesia.

Hypersensitivity to aspirin and other NSAIDs occurs not only within the general population, but mild-to-severe reactions have also been described in patients with mastocytosis. Although the majority of patients with mastocytosis tolerate aspirin and NSAIDs, case reports and one preliminary study suggest that up to 14% of adults report a hypersensitivity reaction (48% have anaphylaxis, 33% have urticaria, and 14% have other reaction), whereas this condition is uncommon in children. Patients who tolerate aspirin and other NSAIDs before a diagnosis of SM generally continue to tolerate these medications, and no avoidance is necessary. In adults with SM without known tolerability of aspirin or NSAIDs, aspirin and NSAIDs should be administered with caution and under medical supervision (extended 2-hour observation period). Graded challenges of an NSAID in any patient with SM who has no history of their use can be used to establish safety. There is not enough evidence to advocate avoidance of aspirin and NSAIDs and pretesting children with mastocytosis. For adults who have did not obtain symptom control with antimediation therapy, aspirin can control SM-related symptoms. If patients with mastocytosis require aspirin for medical treatment but have responded adversely to this medication, desensitization is possible.

Hymenoptera venom is the most common trigger for anaphylaxis in patients with CMD. The cumulative prevalence of HVA is about 5% to 10% of adults with mastocytosis. Patients with SM and HVA have an increased risk of severe systemic reactions compared with subjects without SM. Male sex, a clinical reaction with hypotension and without urticaria and/or angioedema, and increased basal serum tryptase levels are suggestive of CMD. Many of those patients have no MIS, and tryptase levels can in some cases be normal. A good screening test for SM might be detection of the D816V *KIT* mutation in peripheral blood, if available.

VIT is recommended in patients with HVA with SM. VIT in patients with mastocytosis is accompanied by a slightly greater frequency of side effects and a slightly reduced efficacy during VIT. Because severe reactions, including fatalities, have been reported after discontinuation of VIT and there is a paucity of data concerning risk, presently, lifelong VIT should be considered in patients with mastocytosis. However, further studies are addressing this issue, such as with extended injection intervals for maintenance therapy.

Monoclonal antibodies have been used only in relatively few patients with CMD without any description of anaphylaxis in the literature. Thus there is no evidence that the prevalence of reactions to mAbs is increased in patients with SM. *Vice versa*, omalizumab has been successfully used to prevent reactions in patients with recurrent HVA VIT induction or idiopathic anaphylaxis.

Although anaphylaxis to RCMs has also been described in patients with SM, there is yet no evidence that there is a greater risk of anaphylactic reactions to RCMs in patients with mastocytosis compared with the general population. The value of prophylactic administration of premedication in all adults with mastocytosis without previous reactions to RCMs, as done in many centers, remains unproved and has to be further established by more data. Magnetic resonance imaging agents carry no cross-reactive structure and can be used in patients with previous reaction to RCMs. In hypersensitive patients, if another

investigation with iodinated contrast media is needed, a structurally different RCM should be used. In those patients skin testing with undiluted RCMs for skin prick tests and 1:10 diluted RCM for intradermal test is recommended, although results will only be positive in a fraction of patients with RCM hypersensitivity. In those with positive skin test responses, a product eliciting negative skin test responses can be identified for further use. In patients with a negative skin test response or in whom skin tests are not possible, in addition to emergency preparedness and resuscitation facilities nearby, premedication with antihistamines and corticosteroids should be considered, although doctors should not rely on its effectiveness.

Mastocytosis is not a contraindication for vaccination. All vaccines can be administered, although there might be a slightly higher reaction rate in children with mastocytosis compared with the general population. Most of the reactions are mild, and only in exceptional cases have bullous eruptions and more severe MC mediator-derived symptoms been described. Although the evidence is weak and preliminary, the risk might perhaps be increased in children with extensive skin disease, such as those with DCM, to hexavalent vaccines and to the first injection.

REFERENCES

- Valent P, Akin C, Escribano L, Fodinger M, Hartmann K, Brockow K, et al. Standards and standardization in mastocytosis: consensus statements on diagnostics, treatment recommendations and response criteria. *Eur J Clin Invest* 2007;37:435-53.
- Brockow K. Epidemiology, prognosis, and risk factors in mastocytosis. *Immunol Allergy Clin North Am* 2014;34:283-95.
- Nagata H, Okada T, Worobec AS, Semere T, Metcalfe DD. c-kit mutation in a population of patients with mastocytosis. *Int Arch Allergy Immunol* 1997;113:184-6.
- Valent P, Akin C, Metcalfe DD. Mastocytosis 2016: updated WHO classification and novel emerging treatment concepts. *Blood* 2017;129:1420-7.
- Johansson SG, Bieber T, Dahl R, Friedmann PS, Lanier BQ, Lockey RF, et al. Revised nomenclature for allergy for global use: report of the Nomenclature Review Committee of the World Allergy Organization, October 2003. *J Allergy Clin Immunol* 2004;113:832-6.
- Sampson HA, Munoz-Furlong A, Campbell RL, Adkinson NF Jr, Bock SA, Branum A, et al. Second symposium on the definition and management of anaphylaxis: summary report—Second National Institute of Allergy and Infectious Disease/Food Allergy and Anaphylaxis Network symposium. *J Allergy Clin Immunol* 2006;117:391-7.
- Brockow K, Jofer C, Behrendt H, Ring J. Anaphylaxis in patients with mastocytosis: a study on history, clinical features and risk factors in 120 patients. *Allergy* 2008;63:226-32.
- Brosby-Olsen S, Farkas DK, Vestergaard H, Hermann AP, Moller MB, Mortz CG, et al. Risk of solid cancer, cardiovascular disease, anaphylaxis, osteoporosis and fractures in patients with systemic mastocytosis: a nationwide population-based study. *Am J Hematol* 2016;91:1069-75.
- Gonzalez de Olano D, de la Hoz Caballer B, Nunez Lopez R, Sanchez Munoz L, Cuevas Agustin M, Dieguez MC, et al. Prevalence of allergy and anaphylactic symptoms in 210 adult and pediatric patients with mastocytosis in Spain: a study of the Spanish network on mastocytosis (REMA). *Clin Exp Allergy* 2007;37:1547-55.
- Alvarez-Twose I, Vano-Galvan S, Sanchez-Munoz L, Morgado JM, Matito A, Torrel A, et al. Increased serum baseline tryptase levels and extensive skin involvement are predictors for the severity of mast cell activation episodes in children with mastocytosis. *Allergy* 2012;67:813-21.
- Brockow K, Ring J, Alvarez-Twose I, Orfao A, Escribano L. Extensive blistering is a predictor for severe complications in children with mastocytosis. *Allergy* 2012;67:1323-4.
- Gulen T, Hagglund H, Dahlen B, Nilsson G. High prevalence of anaphylaxis in patients with systemic mastocytosis—a single-centre experience. *Clin Exp Allergy* 2014;44:121-9.
- Alvarez-Twose I, Zanotti R, Gonzalez-de-Olano D, Bonadonna P, Vega A, Matito A, et al. Nonaggressive systemic mastocytosis (SM) without skin lesions associated with insect-induced anaphylaxis shows unique features versus other indolent SM. *J Allergy Clin Immunol* 2014;133:520-8.
- Akin C, Scott LM, Kocabas CN, Kushnir-Sukhov N, Brittain E, Noel P, et al. Demonstration of an aberrant mast-cell population with clonal markers in a subset of patients with “idiopathic” anaphylaxis. *Blood* 2007;110:2331-3.
- Sonneck K, Florian S, Mullauer L, Wimazal F, Fodinger M, Sperr WR, et al. Diagnostic and subdiagnostic accumulation of mast cells in the bone marrow of patients with anaphylaxis: monoclonal mast cell activation syndrome. *Int Arch Allergy Immunol* 2007;142:158-64.
- Brockow K, Bonadonna P. Drug allergy in mast cell disease. *Curr Opin Allergy Clin Immunol* 2012;12:354-60.
- Ludolph-Hauser D, Rueff F, Fries C, Schopf P, Przybilla B. Constitutively raised serum concentrations of mast-cell tryptase and severe anaphylactic reactions to Hymenoptera stings. *Lancet* 2001;357:361-2.
- Carter MC, Uzzaman A, Scott LM, Metcalfe DD, Quezado Z. Pediatric mastocytosis: routine anesthetic management for a complex disease. *Anesth Analg* 2008;107:422-7.
- Dewachter P, Castells MC, Hepner DL, Mouton-Faivre C. Perioperative management of patients with mastocytosis. *Anesthesiology* 2014;120:753-9.
- Escribano L, Akin C, Castells M, Orfao A, Metcalfe DD. Mastocytosis: current concepts in diagnosis and treatment. *Ann Hematol* 2002;81:677-90.
- Marone G, Stellato C. Activation of human mast cells and basophils by general anaesthetic drugs. *Monogr Allergy* 1992;30:54-73.
- Stellato C, Casolaro V, Ciccarelli A, Mastronardi P, Mazzarella B, Marone G. General anaesthetics induce only histamine release selectively from human mast cells. *Br J Anaesth* 1991;67:751-8.
- Stellato C, Marone G. Mast cells and basophils in adverse reactions to drugs used during general anesthesia. *Chem Immunol* 1995;62:108-31.
- Bridgman DE, Clarke R, Sadleir PH, Stedmon JJ, Platt P. Systemic mastocytosis presenting as intraoperative anaphylaxis with atypical features: a report of two cases. *Anaesth Intensive Care* 2013;41:116-21.
- Brodier C, Guyot E, Palot M, David P, Rendoing J. [Anesthesia of a child with a cutaneous mastocytosis]. *Cah Anesthesiol* 1993;41:77-9.
- Coleman MA, Libberthson RR, Crone RK, Levine FH. General anesthesia in a child with urticaria pigmentosa. *Anesth Analg* 1980;59:704-6.
- Desborough JP, Taylor I, Hattersley A, Garden A, Wolff A, Bloom SR, et al. Massive histamine release in a patient with systemic mastocytosis. *Br J Anaesth* 1990;65:833-6.
- Greenblatt EP, Chen L. Urticaria pigmentosa: an anesthetic challenge. *J Clin Anesth* 1990;2:108-15.
- Hosking MP, Warner MA. Sudden intraoperative hypotension in a patient with asymptomatic urticaria pigmentosa. *Anesth Analg* 1987;66:344-6.
- Scott HW Jr, Parris WC, Sandidge PC, Oates JA, Roberts LJ 2nd. Hazards in operative management of patients with systemic mastocytosis. *Ann Surg* 1983;197:507-14.
- Smith GB, Gusberg RJ, Jordan RH, Kim B. Histamine levels and cardiovascular responses during splenectomy and splenorenal shunt formation in a patient with systemic mastocytosis. *Anaesthesia* 1987;42:861-7.
- Tirel O, Chaumont A, Ecoffey C. [Circulatory arrest in the course of anesthesia for a child with mastocytosis]. *Ann Fr Anesth Reanim* 2001;20:874-5.
- Vaughan ST, Jones GN. Systemic mastocytosis presenting as profound cardiovascular collapse during anaesthesia. *Anaesthesia* 1998;53:804-7.
- Matito A, Morgado JM, Sanchez-Lopez P, Alvarez-Twose I, Sanchez-Munoz L, Orfao A, et al. Management of anesthesia in adult and pediatric mastocytosis: a study of the Spanish Network on Mastocytosis (REMA) based on 726 anesthetic procedures. *Int Arch Allergy Immunol* 2015;167:47-56.
- Ahmad N, Evans P, Lloyd-Thomas AR. Anesthesia in children with mastocytosis—a case based review. *Paediatr Anaesth* 2009;19:97-107.
- Auvray L, Letourneau B, Freysz M. [Mastocytosis: general anesthesia with remifentanyl and sevoflurane]. *Ann Fr Anesth Reanim* 2001;20:635-8.
- Borgeat A, Ruetsch YA. Anesthesia in a patient with malignant systemic mastocytosis using a total intravenous anesthetic technique. *Anesth Analg* 1998;86:442-4.
- Mertes PM, Alla F, Trechot P, Auroy Y, Jouglu E. Groupe d'Etudes des Reactions Anaphylactoides P. Anaphylaxis during anesthesia in France: an 8-year national survey. *J Allergy Clin Immunol* 2011;128:366-73.
- Stellato C, de Paulis A, Cirillo R, Mastronardi P, Mazzarella B, Marone G. Heterogeneity of human mast cells and basophils in response to muscle relaxants. *Anesthesiology* 1991;74:1078-86.
- Koppert W, Blunk JA, Petersen LJ, Skov P, Rentsch K, Schmelz M. Different patterns of mast cell activation by muscle relaxants in human skin. *Anesthesiology* 2001;95:659-67.
- Doenicke A, Soukup J, Hoerneck R, Moss J. The lack of histamine release with cisatracurium: a double-blind comparison with vecuronium. *Anesth Analg* 1997;84:623-8.

42. Dong SW, Mertes PM, Petitpain N, Hasdenteufel F, Malinovsky JM. GERAP. Hypersensitivity reactions during anesthesia. Results from the ninth French survey (2005-2007). *Minerva Anesthesiol* 2012;78:868-78.
43. Takazawa T, Mitsuahata H, Mertes PM. Sugammadex and rocuronium-induced anaphylaxis. *J Anesth* 2016;30:290-7.
44. Dobkin AB, Byles PH, Neville JF Jr. Neuroendocrine and metabolic effects of general anaesthesia during spontaneous breathing, controlled breathing, milk hypoxia, and mild hypercarbia. *Can Anaesth Soc J* 1966;13:130-71.
45. Luo C, Yuan D, Zhao W, Chen H, Luo G, Su G, et al. Sevoflurane ameliorates intestinal ischemia-reperfusion-induced lung injury by inhibiting the synergistic action between mast cell activation and oxidative stress. *Mol Med Rep* 2015;12:1082-90.
46. Baldo BA, Pham NH. Histamine-releasing and allergenic properties of opioid analgesic drugs: resolving the two. *Anaesth Intensive Care* 2012;40:216-35.
47. Marone G, Stellato C, Mastronardi P, Mazzarella B. Mechanisms of activation of human mast cells and basophils by general anesthetic drugs. *Ann Fr Anesth Reanim* 1993;12:116-25.
48. Stellato C, Cirillo R, de Paulis A, Casolaro V, Patella V, Mastronardi P, et al. Human basophil/mast cell releasability. IX. Heterogeneity of the effects of opioids on mediator release. *Anesthesiology* 1992;77:932-40.
49. Blunk JA, Schmelz M, Zeck S, Skov P, Likar R, Koppert W. Opioid-induced mast cell activation and vascular responses is not mediated by mu-opioid receptors: an in vivo microdialysis study in human skin. *Anesth Analg* 2004;98:364-70.
50. Rosow CE, Philbin DM, Keegan CR, Moss J. Hemodynamics and histamine release during induction with sufentanil or fentanyl. *Anesthesiology* 1984;60:489-91.
51. Lahat A, Ben-Horin S, Lang A, Fudim E, Picard O, Chowers Y. Lidocaine down-regulates nuclear factor-kappaB signalling and inhibits cytokine production and T cell proliferation. *Clin Exp Immunol* 2008;152:320-7.
52. Yanagi H, Sankawa H, Saito H, Iikura Y. Effect of lidocaine on histamine release and Ca²⁺ mobilization from mast cells and basophils. *Acta Anaesthesiol Scand* 1996;40:1138-44.
53. Malinovsky JM, Chiriac AM, Tacquard C, Mertes PM, Demoly P. Allergy to local anesthetics: reality or myth? *Presse Med* 2016;45:753-7.
54. Bhole MV, Manson AL, Seneviratne SL, Misbah SA. IgE-mediated allergy to local anesthetics: separating fact from perception: a UK perspective. *Br J Anaesth* 2012;108:903-11.
55. Dewachter P, Mouton-Faivre C, Cazalaa JB, Carli P, Lortholary O, Hermine O. [Mastocytosis and anaesthesia]. *Ann Fr Anesth Reanim* 2009;28:61-73.
56. Lamson TW, Thomas R. Some untoward effects of acetyl salicylic acid. *JAMA* 1932;99.
57. Klein NJ, Misseldine S. Anesthetic considerations in pediatric mastocytosis: a review. *J Anesth* 2013;27:588-98.
58. Valent P, Akin C, Arock M, Brockow K, Butterfield JH, Carter MC, et al. Definitions, criteria and global classification of mast cell disorders with special reference to mast cell activation syndromes: a consensus proposal. *Int Arch Allergy Immunol* 2012;157:215-25.
59. Guin JD. Treatment of urticaria. *Med Clin North Am* 1982;66:831-49.
60. Dysart BR. Death following ingestion of 5 grains of acetyl salicylic acid. *JAMA* 1933;101.
61. Pleskow WW, Stevenson DD, Mathison DA, Simon RA, Schatz M, Zeiger RS. Aspirin-sensitive rhinosinusitis/asthma: spectrum of adverse reactions to aspirin. *J Allergy Clin Immunol* 1983;71:574-9.
62. Samter M, Beers RF Jr. Intolerance to aspirin. Clinical studies and consideration of its pathogenesis. *Ann Intern Med* 1968;68:975-83.
63. Bochenek G, Nagraba K, Nizankowska E, Szczeklik A. A controlled study of 9alpha,11beta-PGF₂ (a prostaglandin D₂ metabolite) in plasma and urine of patients with bronchial asthma and healthy controls after aspirin challenge. *J Allergy Clin Immunol* 2003;111:743-9.
64. Bosso JV, Schwartz LB, Stevenson DD. Tryptase and histamine release during aspirin-induced respiratory reactions. *J Allergy Clin Immunol* 1991;88:830-7.
65. Lumry WR, Curd JG, Zeiger RS, Pleskow WW, Stevenson DD. Aspirin-sensitive rhinosinusitis: the clinical syndrome and effects of aspirin administration. *J Allergy Clin Immunol* 1983;71:580-7.
66. Brockow K, Akin C, Huber M, Metcalfe DD. Assessment of the extent of cutaneous involvement in children and adults with mastocytosis: relationship to symptomatology, tryptase levels, and bone marrow pathology. *J Am Acad Dermatol* 2003;48:508-16.
67. Muller U, Helbling A, Hunziker T, Wuthrich B, Pecoud A, Gilardi S, et al. Mastocytosis and atopy: a study of 33 patients with urticaria pigmentosa. *Allergy* 1990;45:597-603.
68. Bonadonna P, Perbellini O, Passalacqua G, Caruso B, Colarossi S, Dal Fior D, et al. Clonal mast cell disorders in patients with systemic reactions to Hymenoptera stings and increased serum tryptase levels. *J Allergy Clin Immunol* 2009;123:680-6.
69. Matsuo H, Morimoto K, Akaki T, Kaneko S, Kusatake K, Kuroda T, et al. Exercise and aspirin increase levels of circulating gliadin peptides in patients with wheat-dependent exercise-induced anaphylaxis. *Clin Exp Allergy* 2005;35:461-6.
70. Morita E, Kunie K, Matsuo H. Food-dependent exercise-induced anaphylaxis. *J Dermatol Sci* 2007;47:109-17.
71. Pfeiffer I, Fischer J, Biedermann T. Acetylsalicylic acid dependent anaphylaxis to carrots in a patient with mastocytosis. *J Dtsch Dermatol Ges* 2011;9:230-1.
72. Divekar R, Butterfield J. Urinary 11beta-PGF₂alpha and N-methyl histamine correlate with bone marrow biopsy findings in mast cell disorders. *Allergy* 2015;70:1230-8.
73. Ravi A, Butterfield J, Weiler CR. Mast cell activation syndrome: improved identification by combined determinations of serum tryptase and 24-hour urine 11beta-prostaglandin₂alpha. *J Allergy Clin Immunol Pract* 2014;2:775-8.
74. Roberts LJ 2nd, Sweetman BJ, Lewis RA, Austen KF, Oates JA. Increased production of prostaglandin D₂ in patients with systemic mastocytosis. *N Engl J Med* 1980;303:1400-4.
75. Roberts LJ 2nd, Turk JW, Oates JA. Shock syndrome associated with mastocytosis: pharmacologic reversal of the acute episode and therapeutic prevention of recurrent attacks. *Adv Shock Res* 1982;8:145-52.
76. Butterfield JH. Survey of aspirin administration in systemic mastocytosis. *Prostaglandins Other Lipid Mediat* 2009;88:122-4.
77. Marone G, Spadaro G, Granata F, Triggiani M. Treatment of mastocytosis: pharmacologic basis and current concepts. *Leuk Res* 2001;25:583-94.
78. Roberts LJ 2nd, Fields JP, Oates JA. Mastocytosis without urticaria pigmentosa: a frequently unrecognized cause of recurrent syncope. *Trans Assoc Am Physicians* 1982;95:36-41.
79. Morrow JD, Oates JA, Roberts LJ 2nd, Zackert WE, Mitchell TA, Lazarus G, et al. Increased formation of thromboxane in vivo in humans with mastocytosis. *J Invest Dermatol* 1999;113:93-7.
80. Butterfield JH, Kao PC, Klee GC, Yocum MW. Aspirin idiosyncrasy in systemic mast cell disease: a new look at mediator release during aspirin desensitization. *Mayo Clin Proc* 1995;70:481-7.
81. Butterfield JH, Weiler CR. Prevention of mast cell activation disorder-associated clinical sequelae of excessive prostaglandin D₂ production. *Int Arch Allergy Immunol* 2008;147:338-43.
82. Crawhall JC, Wilkinson RD. Systemic mastocytosis: management of an unusual case with histamine (H₁ and H₂) antagonists and cyclooxygenase inhibition. *Clin Invest Med* 1987;10:1-4.
83. Kootte AM, Haak A, Roberts LJ. The flush syndrome: an expression of systemic mastocytosis with increased prostaglandin D₂ production. *Neth J Med* 1983;26:18-20.
84. Lorcerie B, Arveux I, Chaffert B, Dalac S, Lambert D, Martin F. Aspirin and systemic mastocytosis. *Lancet* 1989;2:1155.
85. Wong JT, Nagy CS, Krinzman SJ, Maclean JA, Bloch KJ. Rapid oral challenge-desensitization for patients with aspirin-related urticaria-angioedema. *J Allergy Clin Immunol* 2000;105:997-1001.
86. Aun MV, Blanca M, Garro LS, Ribeiro MR, Kalil J, Motta AA, et al. Nonsteroidal anti-inflammatory drugs are major causes of drug-induced anaphylaxis. *J Allergy Clin Immunol Pract* 2014;2:414-20.
87. Simons FE. Anaphylaxis. *J Allergy Clin Immunol* 2010;125(suppl):S161-81.
88. Kowalski ML, Makowska JS, Blanca M, Bavbek S, Bochenek G, Bousquet J, et al. Hypersensitivity to nonsteroidal anti-inflammatory drugs (NSAIDs) —classification, diagnosis and management: review of the EAACI/ENDA(®) and GA2LEN/HANNA*. *Allergy* 2011;66:818-29.
89. Sanchez-Matas I, Matito-Bernechea A, Gonzalez de Olano D, Alvarez-Twose I, Sanchez-Munoz L, de la Hoz Caballer B, Escribano L. Prevalence of hypersensitivity reactions to nonsteroidal anti-inflammatory drugs in 212 patients with mastocytosis in Spain. *Allergy* 2009;64:551-98.
90. Seitz CS, Brockow K, Hain J, Trautmann A. Non-steroidal anti-inflammatory drug hypersensitivity: association with elevated basal serum tryptase? *Allergy Asthma Clin Immunol* 2014;10:19.
91. Bonadonna P, Lombardo C, Zanotti R. Mastocytosis and allergic diseases. *J Investig Allergol Clin Immunol* 2014;24:288-97, quiz 3.
92. Gulen T, Haggglund H, Sander B, Dahlen B, Nilsson G. The presence of mast cell clonality in patients with unexplained anaphylaxis. *Clin Exp Allergy* 2014;44:1179-87.
93. Oude Elberink JN, de Monchy JG, Kors JW, van Doormaal JJ, Dubois AE. Fatal anaphylaxis after a yellow jacket sting, despite venom immunotherapy, in two patients with mastocytosis. *J Allergy Clin Immunol* 1997;99:153-4.
94. Rueff F, Placzek M, Przybilla B. Mastocytosis and Hymenoptera venom allergy. *Curr Opin Allergy Clin Immunol* 2006;6:284-8.

95. Alvarez-Twose I, Gonzalez de Olano D, Sanchez-Munoz L, Matito A, Esteban-Lopez MI, Vega A, et al. Clinical, biological, and molecular characteristics of clonal mast cell disorders presenting with systemic mast cell activation symptoms. *J Allergy Clin Immunol* 2010;125:1269-78.e2.
96. Zanotti R, Bonadonna P, Bonifacio M, Artuso A, Skena D, Rossini M, et al. Isolated bone marrow mastocytosis: an underestimated subvariant of indolent systemic mastocytosis. *Haematologica* 2011;96:482-4.
97. Zanotti R, Lombardo C, Passalacqua G, Caimmi C, Bonifacio M, De Matteis G, et al. Clonal mast cell disorders in patients with severe Hymenoptera venom allergy and normal serum tryptase levels. *J Allergy Clin Immunol* 2015;136:135-9.
98. Bonadonna P, Zanotti R, Caruso B, Castellani L, Perbellini O, Colarossi S, et al. Allergen specific immunotherapy is safe and effective in patients with systemic mastocytosis and Hymenoptera allergy. *J Allergy Clin Immunol* 2008;121:256-7.
99. Gonzalez de Olano D, Alvarez-Twose I, Esteban-Lopez MI, Sanchez-Munoz L, de Durana MD, Vega A, et al. Safety and effectiveness of immunotherapy in patients with indolent systemic mastocytosis presenting with Hymenoptera venom anaphylaxis. *J Allergy Clin Immunol* 2008;121:519-26.
100. Bonadonna P, Gonzalez-de-Olano D, Zanotti R, Riccio A, De Ferrari L, Lombardo C, et al. Venom immunotherapy in patients with clonal mast cell disorders: efficacy, safety, and practical considerations. *J Allergy Clin Immunol Pract* 2013;1:474-8.
101. Broesby-Olsen S, Vestergaard H, Mortz CG, Jensen B, Havelund T, Hermann AP, et al. Omalizumab prevents anaphylaxis and improves symptoms in systemic mastocytosis: efficacy and safety observations. *Allergy* 2018;73:230-8.
102. Sokol KC, Ghazi A, Kelly BC, Grant JA. Omalizumab as a desensitizing agent and treatment in mastocytosis: a review of the literature and case report. *J Allergy Clin Immunol Pract* 2014;2:266-70.
103. Michel J, Brockow K, Darsow U, Ring J, Schmidt-Weber CB, Grunwald T, et al. Added sensitivity of component-resolved diagnosis in hymenoptera venom-allergic patients with elevated serum tryptase and/or mastocytosis. *Allergy* 2016;71:651-60.
104. Bonifazi F, Jutel M, Bilo BM, Birnbaum J, Muller U. EAACI Interest Group on Insect Venom Hypersensitivity. Prevention and treatment of hymenoptera venom allergy: guidelines for clinical practice. *Allergy* 2005;60:1459-70.
105. Kors JW, van Doormaal JJ, de Monchy JG. Anaphylactoid shock following Hymenoptera sting as a presenting symptom of systemic mastocytosis. *J Intern Med* 1993;233:255-8.
106. Simioni L, Vianello A, Bonadonna P, Marcer G, Severino M, Pagani M, et al. Efficacy of venom immunotherapy given every 3 or 4 months: a prospective comparison with the conventional regimen. *Ann Allergy Asthma Immunol* 2013;110:51-4.
107. Alonso Diaz de Durana MD, Fernandez-Rivas M, Casas ML, Esteban E, Cuevas M, Tejedor MA. Anaphylaxis during negative penicillin skin prick testing confirmed by elevated serum tryptase. *Allergy* 2003;58:159.
108. Brockow K, Garvey LH, Aberer W, Atanaskovic-Markovic M, Barbaud A, Bilo MB, et al. Skin test concentrations for systemically administered drugs—an ENDA/EAACI Drug Allergy Interest Group position paper. *Allergy* 2013;68:702-12.
109. Skena D, Galvan A, Tessari G, Girolomoni G. Clinical features and course of cutaneous mastocytosis in 133 children. *Br J Dermatol* 2016;174:411-3.
110. Siebenhaar F, Akin C, Bindslev-Jensen C, Maurer M, Broesby-Olsen S. Treatment strategies in mastocytosis. *Immunol Allergy Clin North Am* 2014;34:433-47.
111. Joint Task Force on Practice Parameters, American Academy of Allergy, Asthma, & Immunology, American College of Allergy, Asthma, & Immunology, Joint Council of Allergy, Asthma, & Immunology. Drug allergy: an updated practice parameter. *Ann Allergy Asthma Immunol* 2010;105:259-73.
112. Brennan PJ, Rodriguez Bouza T, Hsu FI, Sloane DE, Castells MC. Hypersensitivity reactions to mAbs: 105 desensitizations in 23 patients, from evaluation to treatment. *J Allergy Clin Immunol* 2009;124:1259-66.
113. Escribano L, Diaz Agustin B, Bravo P, Navalon R, Almeida J, Orfao A. Immunophenotype of bone marrow mast cells in indolent systemic mast cell disease in adults. *Leuk Lymphoma* 1999;35:227-35.
114. Carter MC, Robyn JA, Bressler PB, Walker JC, Shapiro GG, Metcalfe DD. Omalizumab for the treatment of unprovoked anaphylaxis in patients with systemic mastocytosis. *J Allergy Clin Immunol* 2007;119:1550-1.
115. Casale TB, Busse WW, Kline JN, Ballas ZK, Moss MH, Townley RG, et al. Omalizumab pretreatment decreases acute reactions after rush immunotherapy for ragweed-induced seasonal allergic rhinitis. *J Allergy Clin Immunol* 2006;117:134-40.
116. Castells MC, Hornick JL, Akin C. Anaphylaxis after hymenoptera sting: is it venom allergy, a clonal disorder, or both? *J Allergy Clin Immunol Pract* 2015;3:350-5.
117. Kontou-Fili K. High omalizumab dose controls recurrent reactions to venom immunotherapy in indolent systemic mastocytosis. *Allergy* 2008;63:376-8.
118. Kontou-Fili K, Filis CI. Prolonged high-dose omalizumab is required to control reactions to venom immunotherapy in mastocytosis. *Allergy* 2009;64:1384-5.
119. Douglass JA, Carroll K, Voskamp A, Bourke P, Wei A, O'Hehir RE. Omalizumab is effective in treating systemic mastocytosis in a nonatopic patient. *Allergy* 2010;65:926-7.
120. Brown SG, Wiese MD, van Eeden P, Stone SF, Chuter CL, Gunner J, et al. Ultrasound versus semirush initiation of insect venom immunotherapy: a randomized controlled trial. *J Allergy Clin Immunol* 2012;130:162-8.
121. Pereira-Santos MC, Baptista AP, Melo A, Alves RR, Soares RS, Pedro E, et al. Expansion of circulating Foxp3+D25bright CD4+ T cells during specific venom immunotherapy. *Clin Exp Allergy* 2008;38:291-7.
122. Quintas-Cardama A, Amin HM, Kantarjian H, Verstovsek S. Treatment of aggressive systemic mastocytosis with daclizumab. *Leuk Lymphoma* 2010;51:540-2.
123. Bandmann HJ, Kaess H, Langer HD. [Mastocytosis simulating a food allergy]. *Hautarzt* 1983;34:217-20.
124. Valabhji J, Robinson S, Johnston D, Bellamy M, Davies W, Bain BJ. Unexplained loss of consciousness: systemic mastocytosis. *J R Soc Med* 2000;93:141-2.
125. Weingarten TN, Volcheck GW, Sprung J. Anaphylactoid reaction to intravenous contrast in patient with systemic mastocytosis. *Anaesth Intensive Care* 2009;37:646-9.
126. Brockow K, Romano A, Aberer W, Bircher AJ, Barbaud A, Bonadonna P, et al. Skin testing in patients with hypersensitivity reactions to iodinated contrast media—a European multicenter study. *Allergy* 2009;64:234-41.
127. Brockow K, Christiansen C, Kanny G, Clement O, Barbaud A, Bircher A, et al. Management of hypersensitivity reactions to iodinated contrast media. *Allergy* 2005;60:150-8.
128. Bonadonna P, Pagani M, Aberer W, Bilo MB, Brockow K, Oude Elberink H, et al. Drug hypersensitivity in clonal mast cell disorders: ENDA/EAACI position paper. *Allergy* 2015;70:755-63.
129. Caimmi S, Benyahia B, Suau D, Bousquet-Rouanet L, Caimmi D, Bousquet PJ, et al. Clinical value of negative skin tests to iodinated contrast media. *Clin Exp Allergy* 2010;40:805-10.
130. Tramer MR, von Elm E, Loubeyre P, Hauser C. Pharmacological prevention of serious anaphylactic reactions due to iodinated contrast media: systematic review. *BMJ* 2006;333:675.
131. Roush SW, Murphy TV. Vaccine-Preventable Disease Table Working Group. Historical comparisons of morbidity and mortality for vaccine-preventable diseases in the United States. *JAMA* 2007;298:2155-63.
132. Kelso JM, Greenhawt MJ, Li JT, Nicklas RA, Bernstein DI, Blessing-Moore J, et al. Adverse reactions to vaccines practice parameter 2012 update. *J Allergy Clin Immunol* 2012;130:25-43.
133. Kattan JD, Konstantinou GN, Cox AL, Nowak-Wegrzyn A, Gimenez G, Sampson HA, et al. Anaphylaxis to diphtheria, tetanus, and pertussis vaccines among children with cow's milk allergy. *J Allergy Clin Immunol* 2011;128:215-8.
134. Kwittken PL, Rosen S, Sweinberg SK. MMR vaccine and neomycin allergy. *Am J Dis Child* 1993;147:128-9.
135. Russell M, Pool V, Kelso JM, Tomazic-Jezic VJ. Vaccination of persons allergic to latex: a review of safety data in the Vaccine Adverse Event Reporting System (VAERS). *Vaccine* 2004;23:664-7.
136. Slater JE, Rabin RL, Martin D. Comments on cow's milk allergy and diphtheria, tetanus, and pertussis vaccines. *J Allergy Clin Immunol* 2011;128:434, author reply 435.
137. Zheng W, Dreskin SC. Thimerosal in influenza vaccine: an immediate hypersensitivity reaction. *Ann Allergy Asthma Immunol* 2007;99:574-5.
138. Kelso JM, Jones RT, Yunginger JW. Anaphylaxis to measles, mumps, and rubella vaccine mediated by IgE to gelatin. *J Allergy Clin Immunol* 1993;91:867-72.
139. Sakaguchi M, Miyazawa H, Inouye S. Specific IgE and IgG to gelatin in children with systemic cutaneous reactions to Japanese encephalitis vaccines. *Allergy* 2001;56:536-9.
140. Sakaguchi M, Nakayama T, Inouye S. Food allergy to gelatin in children with systemic immediate-type reactions, including anaphylaxis, to vaccines. *J Allergy Clin Immunol* 1996;98:1058-61.
141. Sakaguchi M, Yamanaka T, Ikeda K, Sano Y, Fujita H, Miura T, et al. IgE-mediated systemic reactions to gelatin included in the varicella vaccine. *J Allergy Clin Immunol* 1997;99:263-4.
142. Nakayama T, Aizawa C. Change in gelatin content of vaccines associated with reduction in reports of allergic reactions. *J Allergy Clin Immunol* 2000;106:591-2.

143. Zent O, Hennig R. Post-marketing surveillance of immediate allergic reactions: polygeline-based versus polygeline-free pediatric TBE vaccine. *Vaccine* 2004; 23:579-84.
144. Chung EY, Huang L, Schneider L. Safety of influenza vaccine administration in egg-allergic patients. *Pediatrics* 2010;125:e1024-30.
145. Gagnon R, Primeau MN, Des Roches A, Lemire C, Kagan R, Carr S, et al. Safe vaccination of patients with egg allergy with an adjuvanted pandemic H1N1 vaccine. *J Allergy Clin Immunol* 2010;126:317-23.
146. Greenhawt MJ, Spergel JM, Rank MA, Green TD, Mansoor D, Sharma H, et al. Safe administration of the seasonal trivalent influenza vaccine to children with severe egg allergy. *Ann Allergy Asthma Immunol* 2012;109:426-30.
147. Howe LE, Conlon AS, Greenhawt MJ, Sanders GM. Safe administration of seasonal influenza vaccine to children with egg allergy of all severities. *Ann Allergy Asthma Immunol* 2011;106:446-7.
148. James JM, Zeiger RS, Lester MR, Fasano MB, Gern JE, Mansfield LE, et al. Safe administration of influenza vaccine to patients with egg allergy. *J Pediatr* 1998; 133:624-8.
149. Bankova LG, Walter JE, Iyengar SR, Lorenzo ME, Hornick JL, Castells MC. Generalized bullous eruption after routine vaccination in a child with diffuse cutaneous mastocytosis. *J Allergy Clin Immunol Pract* 2013;1:94-6.
150. Koh MJ, Chong WS. Red plaque after hepatitis B vaccination. *Pediatr Dermatol* 2008;25:381-2.
151. Poulton JK, Kauffman CL, Lutz LL, Sina B. Solitary mastocytoma arising at a hepatitis B vaccination site. *Cutis* 1999;63:37-40.
152. Parente R, Pucino V, Magliacane D, Petraroli A, Loffredo S, Marone G, et al. Evaluation of vaccination safety in children with mastocytosis. *Pediatr Allergy Immunol* 2017;28:93-5.
153. Zanoni G, Zanotti R, Schena D, Sabbadini C, Opri R, Bonadonna P. Vaccination management in children and adults with mastocytosis. *Clin Exp Allergy* 2017;47:593-6.